

Case study of sudden onset, bilateral auditory, visual and vestibular neuropathy

Smalley J, Hole K & McCarthy C



Nottingham University Hospitals
NHS Trust

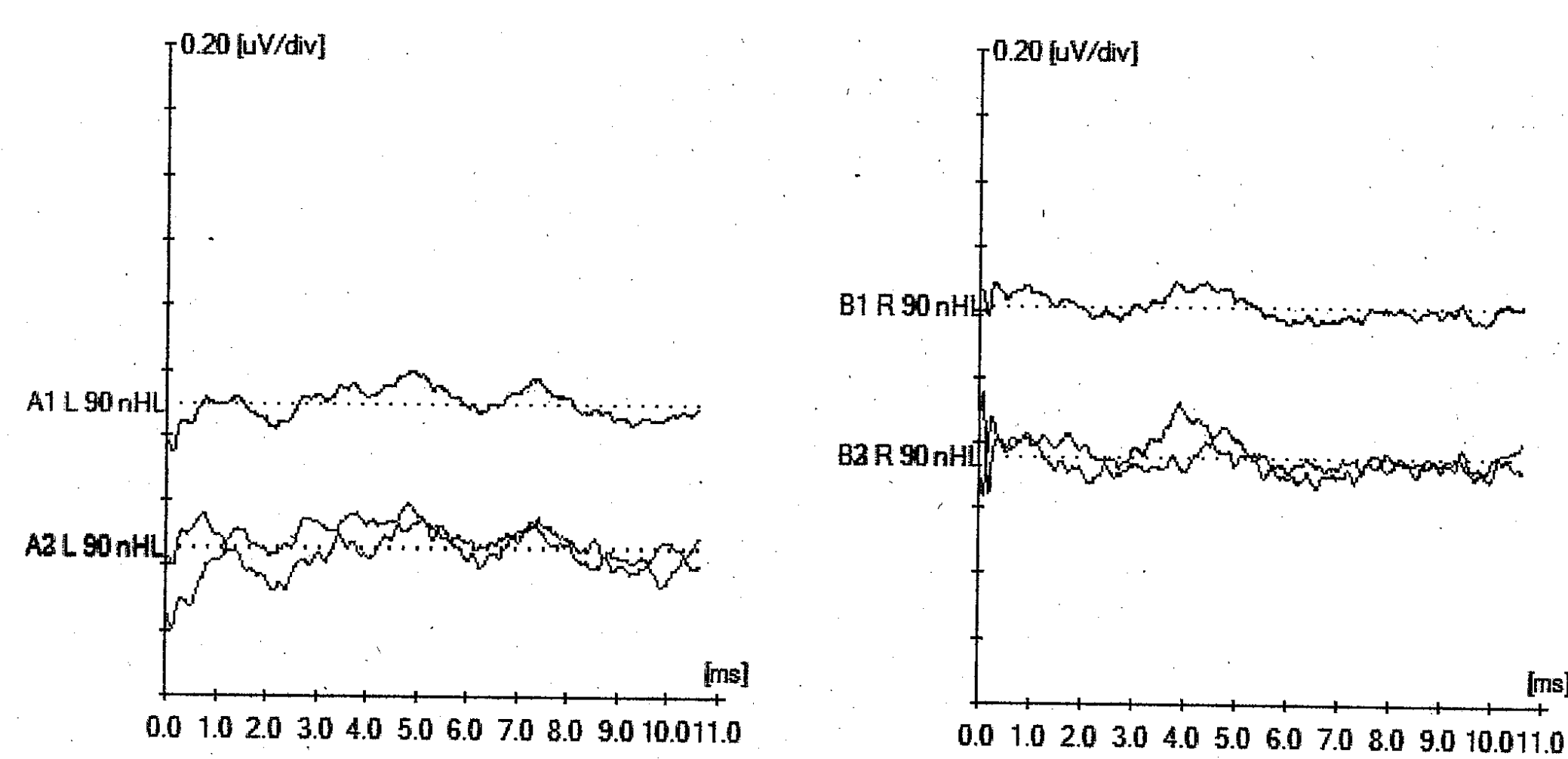
Brief Overview of Case

- 66 year old afro-caribbean male
- No previous audiological or neurological significant history
- Keen runner (run marathons and runs regularly)
 - No recent foreign travel
- On no medications and not seen GP for several years
- Presented via A+E and admitted with sudden onset blindness and profound hearing loss

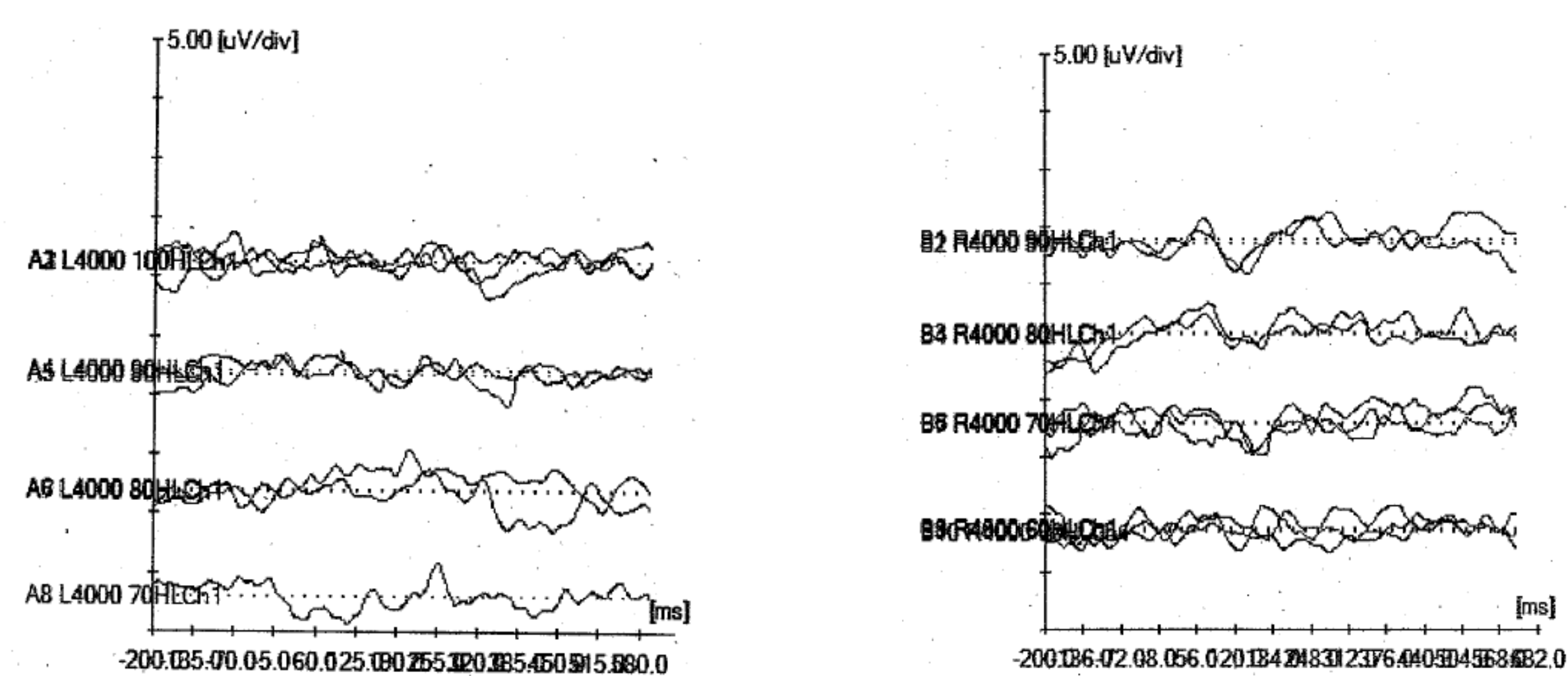
Tests performed

Over the 6 weeks in hospital patient had the following tests:

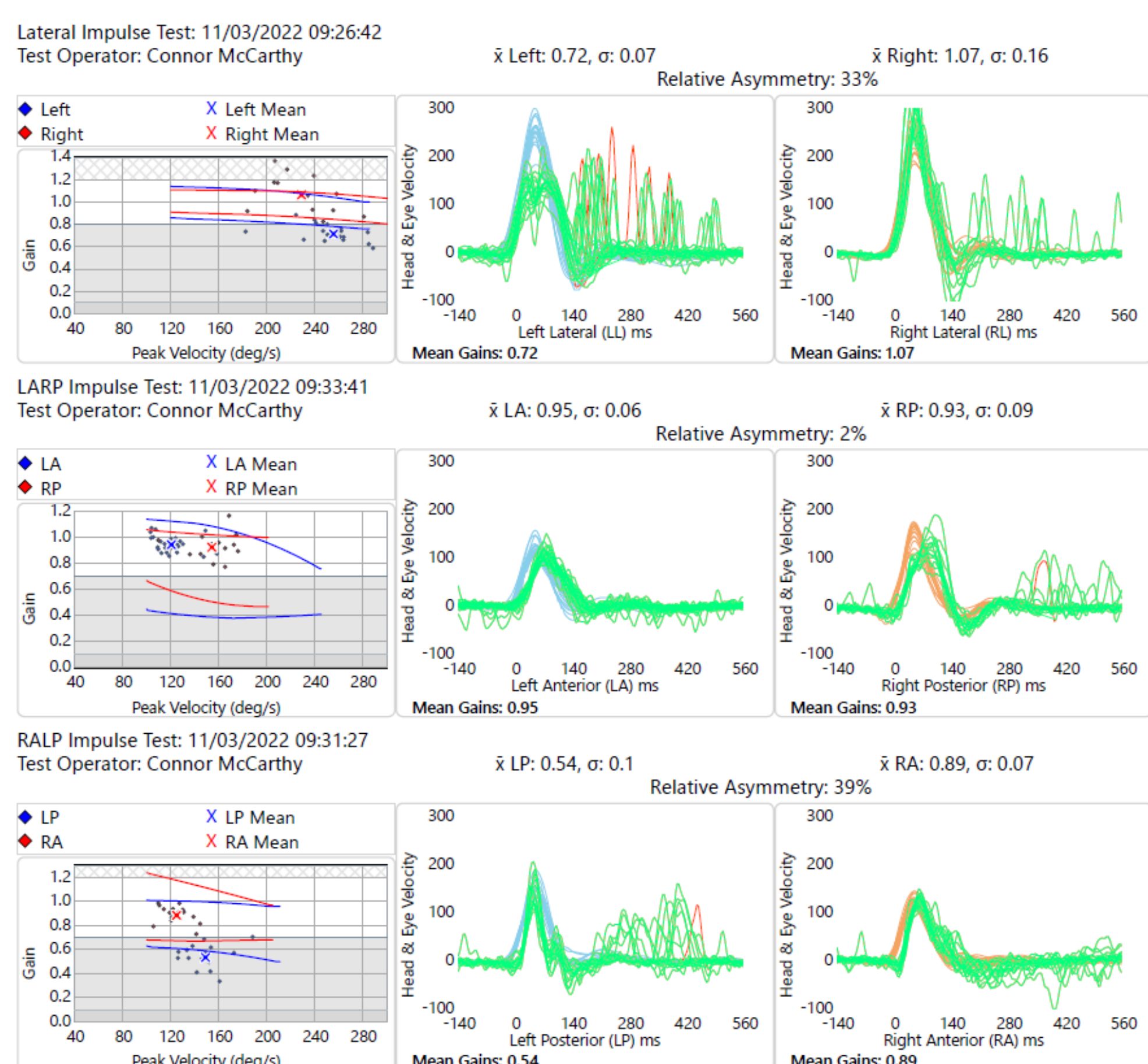
- Full neurological work up including EEG
- Visual evoked response testing (PERG, SERG, VEP, MFVEP, MFERG)
- Auditory evoked response testing (PTA, Tympanometry, OAE, ACR, NABR, TABR)
 - Vestibular function tests – vHIT, VNG



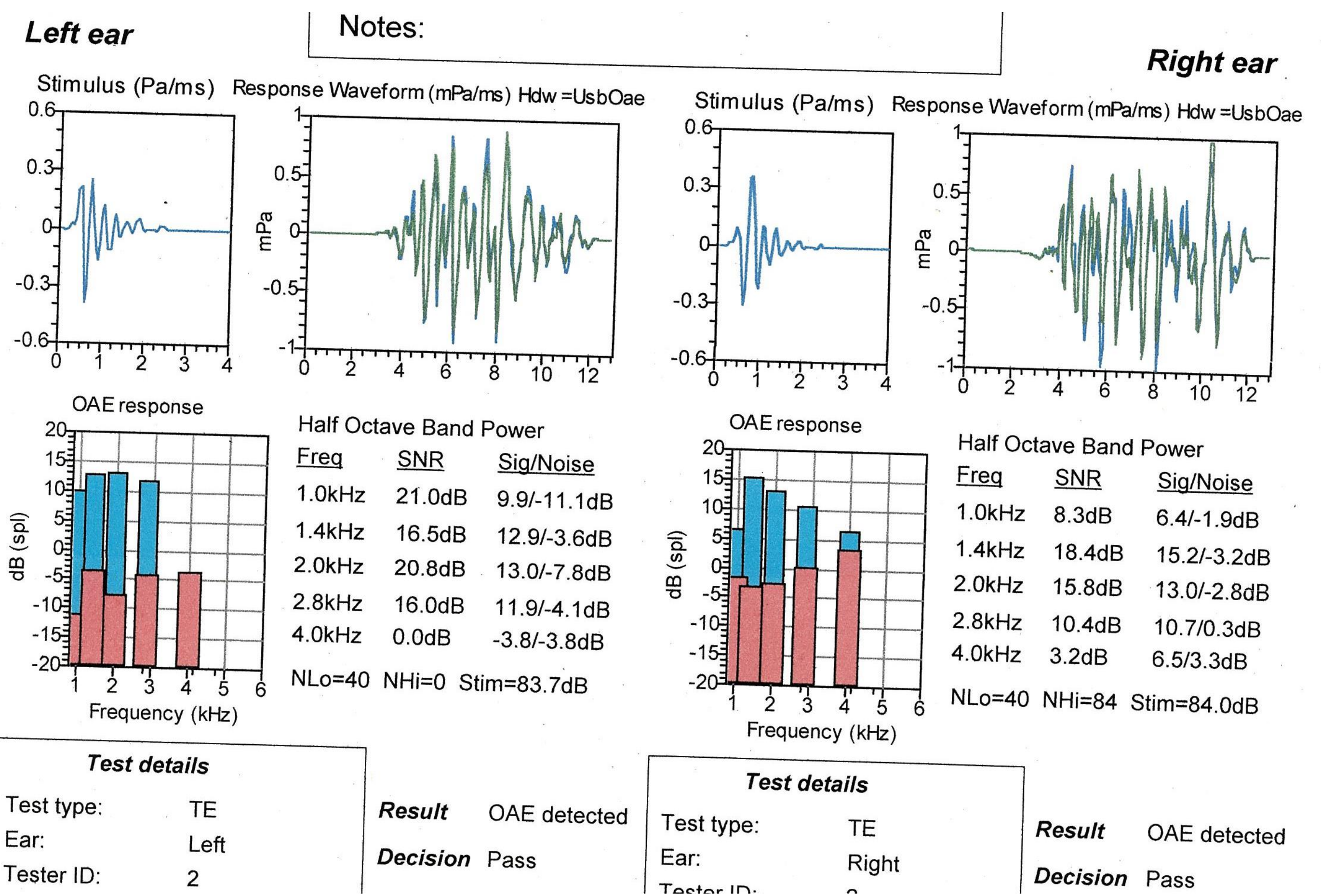
90dBnHL Neurological Click ABR



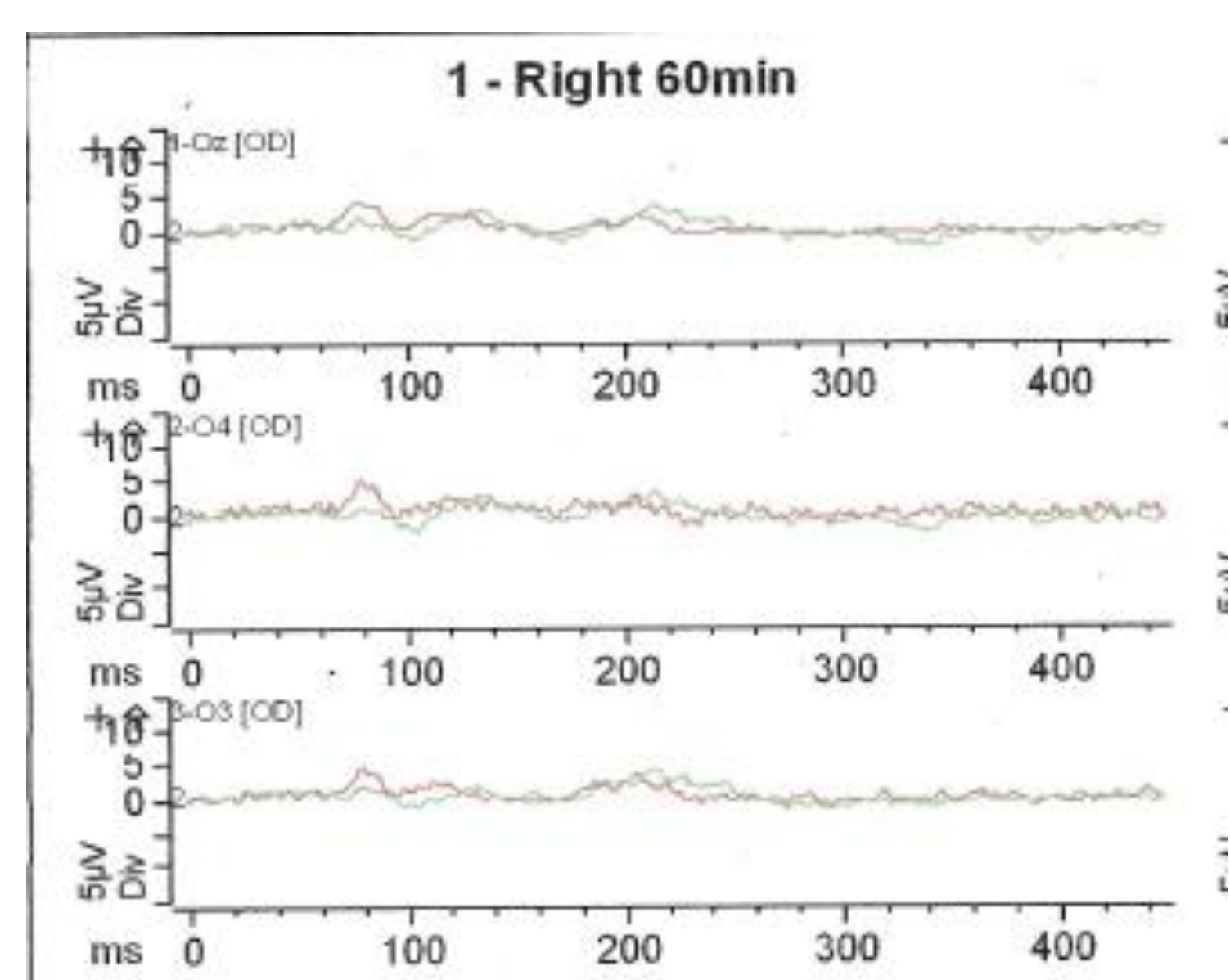
4kHz Cortical Responses



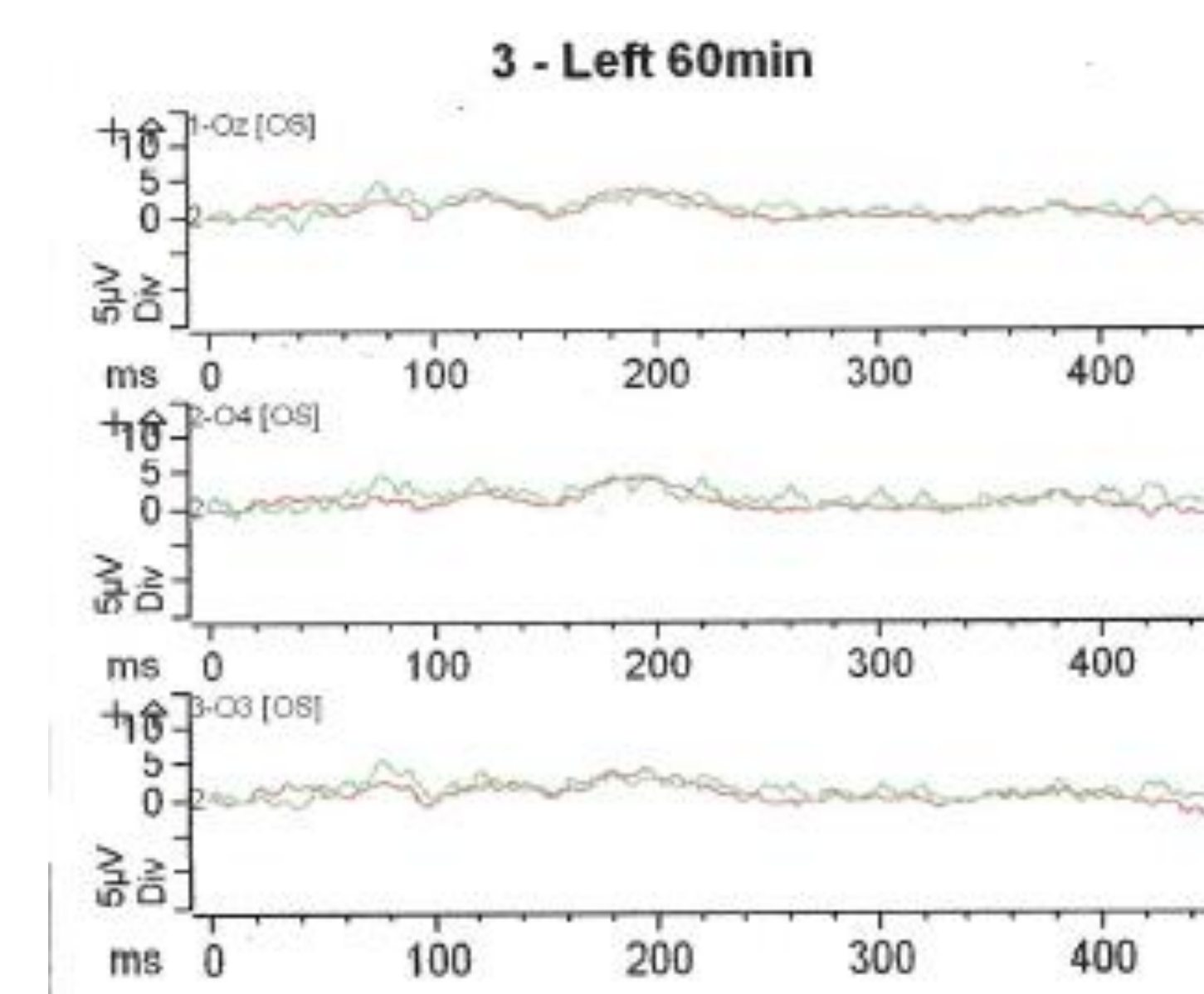
vHIT



TE-OAEs



VEP



Results

- Profound pure-tone audiometry and cortical thresholds bilaterally
- Present TE-OAEs bilaterally
- Absent / poor morphology 90dBnHL click neurological ABR
- Abnormal left horizontal canal vHIT
- Absent / vastly reduced VEP's

Discussion

- Results appear to show sudden onset bilateral auditory and visual neuropathy of unknown cause
- Not progressing well with hearing aid but does not want to consider CI
- Investigations have shown no clear cause (possible carbon monoxide history with faulty boiler)